

# Clinical Implementation of Second-generation Minimally Invasive Image-guided Cochlear Implantation Surgery

\*Robert F. Labadie, †Katherine Riojas, \*Kathleen Von Wahlde, †Jason Mitchell, †Trevor Bruns, †Robert Webster III, ‡Benoit Dawant, ‡J. Michael Fitzpatrick, and ‡Jack Noble

\*Department of Otolaryngology—Head and Neck Surgery, Vanderbilt University Medical Center; †Department of Mechanical Engineering; and ‡Department of Electrical Engineering and Computer Science, Vanderbilt University, Nashville, Tennessee

**Objective:** Minimally invasive, image-guided cochlear implantation (CI) surgery consists of drilling a precise tunnel from the surface of the mastoid cortex through the facial recess to target the scala tympani. In the first set of clinical trials of this technique, heat-induced facial nerve palsy (House-Brackmann II/VI) occurred on a patient on the last day of the initial trial which was scheduled to be halted secondary to a change in the regulatory requirements dictated by the 2012 the Food and Drug Administration Safety and Innovation Act requiring Investigational Device Exemption approval for previously exempted customized medical device testing. To address this adverse event, extensive changes were made to the drilling protocol; additionally, a custom insertion tool was developed. To address the Food and Drug Administration Safety and Innovation Act, an Investigational Device Exemption was submitted and, subsequently approved. Herein is described our first clinical implementation of the modified technique.

**Patient:** Seventy-year-old with profound, postlingual sensorineural hearing loss who had previously undergone right CI via traditional approach in 2015.

**Intervention:** Minimally invasive image-guided left CI.

**Main Outcome Measure:** Time of intervention, final location of CI electrode array within cochlea.

**Results:** Surgery took 155 minutes of which the largest components (in descending order) were soft tissue work, closure, and drilling. Full scala tympani insertion with angular insertion depth of 557 degrees of the electrode array was achieved. There were no complications, and the patient had an uneventful recovery and activation.

**Conclusions:** Minimally invasive, image-guided CI surgery is achievable and reduces the mastoid depression associated with traditional CI surgery.

**ClinicalTrials.gov information:** Study NCT03101917, *Microtable Microstereotactic Frame and Drill Press and Associated Method for Cochlear Implantation*

**Level of Evidence:** Case Report. **Key Words:** Cochlear implantation—Image-guided surgery—Minimally invasive.

*Otol Neurotol* 42:702–705, 2021.

## OBJECTIVE

Computer-guided interventions—such as laser-assisted in-situ keratomileusis, daVinci-assisted transoral robotic surgery, and image-guided neurosurgical and rhinological procedures—offer the prospect of improved accuracy with more consistent results. Within the field of otology, one application of computer guidance is minimally invasive, image-guided cochlear implantation (CI) in which a linear path from the surface of the temporal bone through the facial recess and into the scala tympani (ST) is specified on a preoperative computed tomography (CT) scan. Within the operating room, at least three fiducial markers (the minimum necessary for triangulation/three-dimensional guidance) are placed surrounding the region of interest (e.g., at the mastoid tip, superior to the external auditory canal (EAC), and approximately at the midpoint of the sigmoid sinus). An intra-operative CT (iCT) scan is taken to link the preoperative plan to the anatomy via the markers. At this

Address correspondence and reprint requests to Robert F. Labadie, M.D., Ph.D., Department of Otolaryngology—Head and Neck Surgery, 10269 Medical Center East, South Tower, Vanderbilt University Medical Center, Nashville, TN 37232-8606; E-mail: robert.labadie@vumc.org

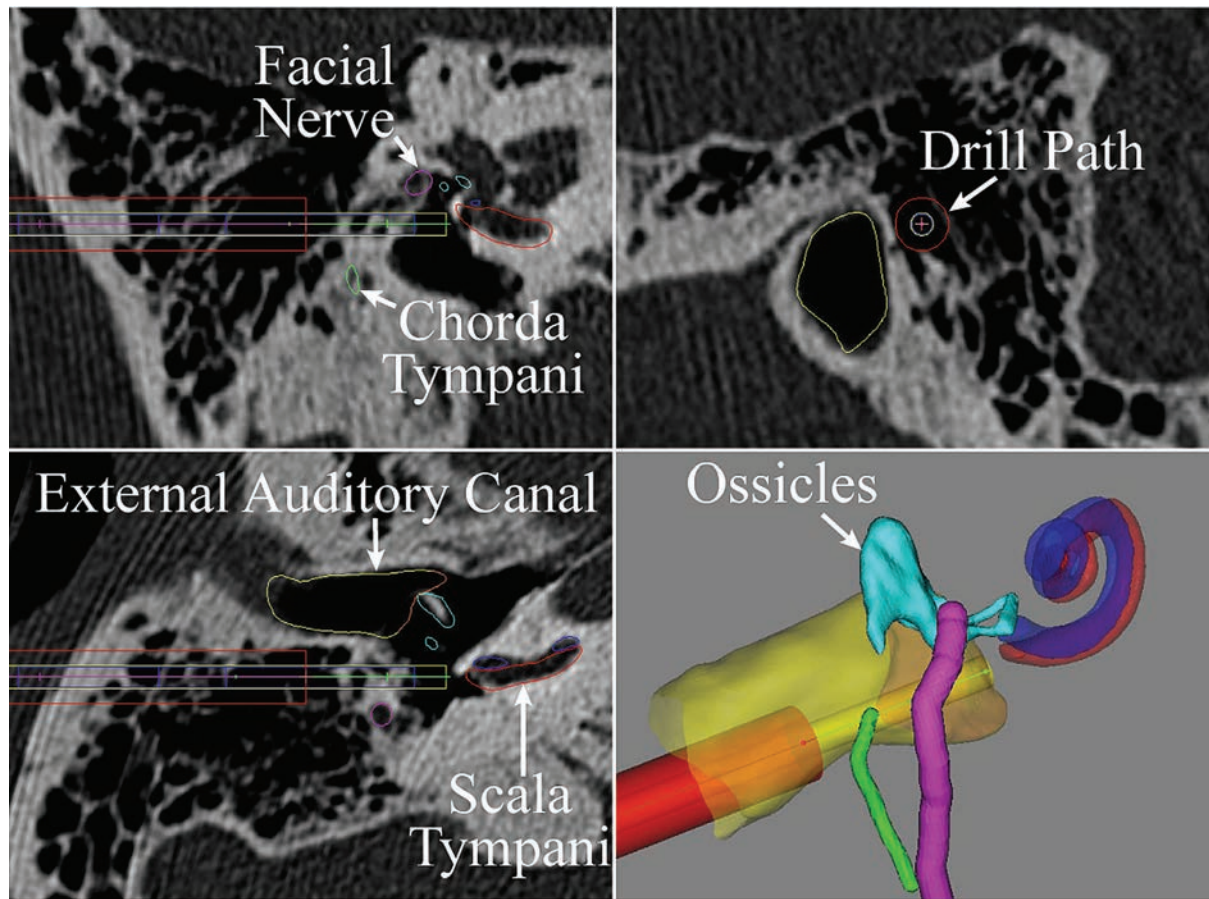
The project described was supported by Award Number R01DC008408 from the National Institute on Deafness and Other Communication Disorders (NIDCD), the National Science Foundation (NSF) Graduate Research Fellowship Program DGE-1445197/1937963, and the the National Center for Advancing Translational Sciences (NCATS) Clinical Translational Science Award Number 5UL1TR002243. The content is solely the responsibility of the authors and does not necessarily represent the official views of the NIDCD, NSF, NCATS, or the National Institutes of Health.

R.F.L. is a consultant for Advanced Bionics and Spiral Therapeutics.

J.M.F. is owner of a company that has licensed the Microtable microstereotactic frame technology from Vanderbilt University for neurosurgical applications.

Supplemental digital content is available in the text.

DOI: 10.1097/MAO.0000000000003025



**FIG. 1.** Preoperative plan on axial (lower left), coronal (upper left), and sagittal (upper right) CT views and 3D rendering (bottom right). Facial nerve (magenta), chorda tympani (green), ear canal (yellow), ossicles (turquoise), scala tympani (red), scala vestibuli (blue), and drill path (lateral—red, medial—dark yellow). The anatomical segmentations and plan are verified before surgery. CT indicates computed tomography.

point, the planned linear path can be realized by positioning a multiarticular arm (1) (a.k.a. robot) or by creating a customized microstereotactic frame to mount on the fiducials (2). Drilling then commences along the path (Fig. 1), and middle ear work (i.e., round window (RW) overhang take-down and entry) is done via an endaural approach.

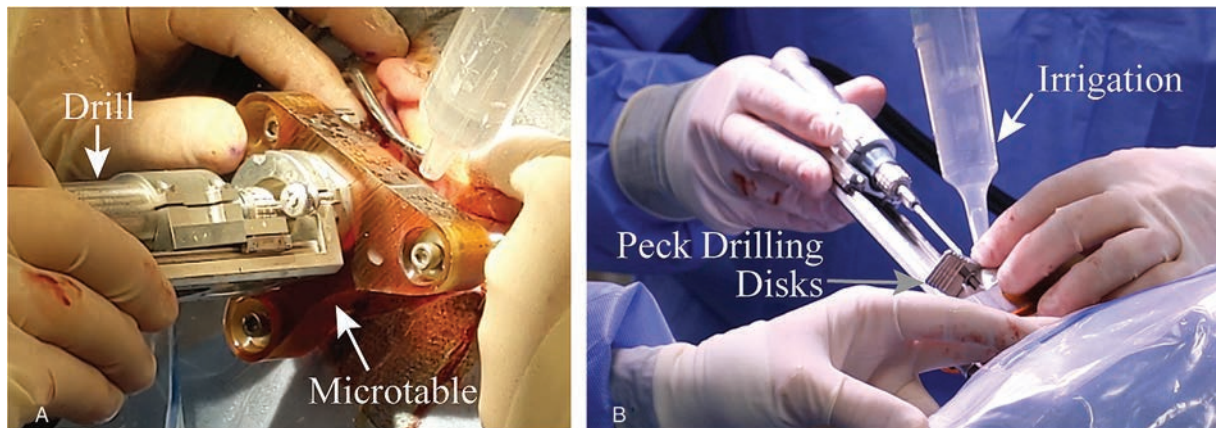
Both robotic (1) and customized microstereotactic frame (2) approaches have been clinically translated with patients reporting less postoperative pain and having more preservation of healthy tissue. Pros and cons are associated with each approach. The robotic approach is more versatile but more costly requiring capital expenditure for both the robot and an image-guided system to track the robot and patient. The microstereotactic approach requires machining expertise and a computer-numeric-control (CNC) machine to create the customized frame “on the fly” while the surgeon is performing other components of the surgery (e.g., soft tissue work). The microstereotactic frame approach was implemented before the multiarticulated arm robot approach but had one patient in the first cohort of nine patients who awoke from general anesthesia with a facial nerve palsy secondary to heat generation during

drilling. Corrective action was taken to prevent this complication from recurring including redesigning the drill bit and implementing incremental peck drilling with continuous irrigation which was shown in temporal bones to result in decreased temperatures near the facial nerve as compared with the previous technique (3).

Concurrent with drilling protocols being redesigned, to address the new regulatory requirements of medical device research imposed by the Food and Drug Administration (FDA) Safety and Innovation Act of 2012, an early feasibility investigational device exemption (IDE) proposal was submitted. This laborious, iterative process took 4 years and resulted in approval in 2016. This IDE was amended in 2019 to include a novel electrode array (EA) insertion tool (4). The objective of this clinical capsule report is to report the first case of the IDE-regulated minimally invasive image-guided CI surgery using the new drilling protocols and the novel EA insertion tool.

## PATIENT

A 70-year-old woman who had undergone right CI surgery in 2015 with a MED-EL (Innsbruck, Austria)



**FIG. 2.** (A) Microstereotactic frame (a.k.a. Microtable) attached to patient (left external ear visible top right of panel) and (B) incremental peck drilling (disks of thickness  $< 1$  mm to limit each drill advance) with copious irrigation during and between pecks employed during medial drilling near the facial nerve.

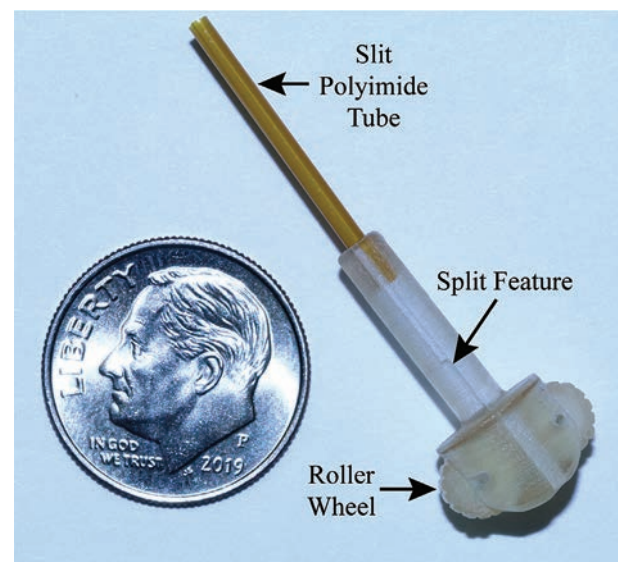
FLEX28 EA array (complete ST insertion, 539 degrees angular insertion depth [AID]). The patient was disappointed by the cosmetically displeasing mastoid depression associated with traditional surgery and requested (and awaited FDA IDE approval for) the minimally invasive, image-guided approach.

### INTERVENTION

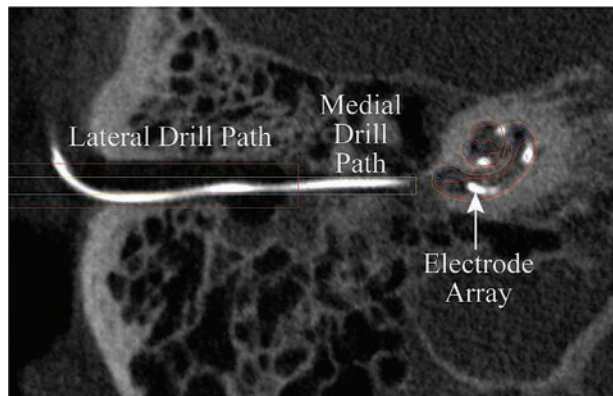
In February 2020, left CI surgery via the minimally invasive, image-guided technique was performed (see video, supplemental digital content, available on-line, <http://links.lww.com/MAO/B173>). This technique involved planning on the preoperative CT scan (Fig. 1). On the day of surgery, five incisions were made as follows: three stab incisions for fiducial markers (mastoid tip, superior to the EAC, and mid-sigmoid sinus), one approximately 3 cm long incision for the internal receiver, and one approximately 2 cm long incision for drill access to the surface of the temporal bone. After placing the bone-implanted fiducial markers, the first iCT scan was taken which was linked to the preoperative plan enabling calculation of the customized stereotactic frame dimensions. The frame was then manufactured using a standard CNC machine while the surgeon performed soft tissue work including access to the middle ear via a tympanomeatal flap and opening of the cochlea by taking down the RW overhang and reflecting the RW membrane inferiorly. Additionally, the pocket for the internal receiver was prepared. At this point, the microstereotactic frame was received in the operating room after being sterilized. It was attached to the fiducial markers via ball-and-socket joints, and the drill mounted as shown in Figure 2A.

Drilling commenced in two stages—a wider lateral tunnel (3.8 mm diameter) and a narrower medial tunnel (1.6 mm diameter). In between the lateral and medial drilling, a second CT was obtained to ensure that the drilling was on course. The medial drilling, through the facial recess to the middle ear, was done using peck

drilling ( $< 1$  mm drill steps followed by 30-s rest periods during which the drill bit was fully withdrawn and irrigated with cool saline) as shown in Figure 2B. Next, after a small incision to bury the internal receiver, the EA was threaded under the skin to the entry of the tunnel (the edges were rounded to protect the transmitting wires) and guided into the cochlea using the insertion tool. Previously described (4), the insertion tool consists of paired entry chambers 3D printed with biocompatible dental resin which slide apart after EA insertion to allow removal of the tool (Fig. 3). The EA is advanced using roller wheels which slightly compress the transmitting



**FIG. 3.** Insertion tool consisting of paired lateral entry chambers to allow removal around the electrode array (EA), roller wheel assembly to advance the transmitting wires and EA, and distal tip of slit polyimide tubing which guides the EA across the middle ear and into the cochlea. In practice, the insertion tube is inserted down the drilled tunnel with the roller wheels positioned just above the surface of the mastoid and the polyimide tube positioned just outside the cochlea.



**FIG. 4.** Postoperative CT scan showing linear drill path and EA coiled within the ST component of the cochlea to a depth of 557 degrees. CT indicates computed tomography; EA, electrode array; ST, scala tympani.

wires of the EA. The distal tip of one of the entry chambers has a slit polyimide tube of 1.5 mm outer diameter which traverses the middle ear and directs the EA into ST. After placement of the EA and removal of the tool, a small piece of temporalis fascia from one of the incisions was packed around the EA as it entered the cochlea, the tympanomeatal flap was reapproximated and held in place with a piece of mupirocin-coated gelfoam, and the incisions were closed with 3-0 Vicryl subcutaneous and 5-0 plain gut superficially. During closure, a member of the audiological team performed impedance and neural response testing. Before breaking down the sterile field, a third and final iCT was obtained to assess EA location.

#### MAIN OUTCOME MEASURE

Time of intervention was recorded by a member of the research team and postoperative EA position within the cochlea was evaluated in the operating room using image processing (5) after the final iCT was taken and during closure.

#### RESULTS

The surgery took 155 minutes from skin incision to skin closure of which the largest component was soft tissue work (middle ear exploration and subcutaneous pocket creation) at 34 minutes 10 seconds during which

time the microstereotactic frame was constructed and sterilized (22% of total intervention), closure at 30 minutes during which audiological testing and image analysis was done concurrently (19% of total intervention), both lateral and medial drilling at 23.5 minutes (15% of total intervention), and the 3 iCT scans at 16 minutes total (10% of total intervention). Complete insertion of a MED-EL (Innsbruck, Austria) FLEX28 EA was achieved with 557 degrees AID (Fig. 4). This depth compared favorably with her contralateral, traditional surgery side of 539 degrees AID. Postoperative recovery was uncomplicated.

#### CONCLUSIONS

Minimally invasive, image-guided CI surgery with the technology described is achievable with good short-term results (ST insertion over 1.5 turns of the cochlea). This technique may be beneficial for patients where the cosmesis of a mastoid depression is of concern, for those patients who wish to preserve healthy tissue, and/or for those patients where tight geometric constraints between the sigmoid and EAC limit surgical visualization.

**Acknowledgment:** The authors thank Neal P. Dillon, Ph.D., a former member of our laboratory who is now employed at Virtuoso Surgical, Inc. who shared previous knowledge base with current members of the laboratory and made himself available for backup on the day of surgery.

#### REFERENCES

1. Caversaccio M, Gavaghan K, Wimmer W, et al. Robotic cochlear implantation: Surgical procedure and first clinical experience. *Acta Otolaryngol* 2017;137:447–54.
2. Labadie RF, Balachandran R, Noble JH, et al. Minimally invasive image-guided cochlear implantation surgery: First report of clinical implementation. *Laryngoscope* 2014;124:1915–22.
3. Dillon NP, Balachandran R, Fitzpatrick JM, et al. Pre-operative screening and manual drilling strategies to reduce the risk of thermal injury during minimally invasive cochlear implantation surgery. *Ann Biomed Eng* 2017;45:2184–95.
4. Riojas KE, Narasimhan N, Morrel WG, et al. A new manual insertion tool for minimally invasive, image-guided cochlear implant surgery. *Proc. SPIE 10951, Medical Imaging 2019: Image-Guided Procedures, Robotic Interventions, and Modeling*, 109510J (8 March 2019); Available at: <https://doi.org/10.1117/12.2512471>.
5. Zhao Y, Labadie RF, Dawant BM, Noble JH. Automatic graph-based method for localization of cochlear implant electrode arrays in clinical CT with sub-voxel accuracy. *J Med Imaging (Bellingham)* 2018;5:035001.